

The Fontan Procedure for Single-Ventricle Physiology

Melissa Beaudet Jones, MSN, APRN, CPNP-AC

The Fontan procedure is the final procedure in staged palliation for patients with functional single-ventricle physiology. The goal of the procedure is to separate systemic and pulmonary blood flow by directing systemic venous return through the Fontan connection to the pulmonary arteries and the lungs without ventricular contribution. Following the procedure, pulmonary blood flow is completely passive and dependent on pressure gradients, resulting in complex postoperative cardiopulmonary interactions. Understanding the physiology is essential to effectively manage these patients. Critical care nurses caring for patients after a Fontan procedure must understand preoperative data, risk factors, and unique postoperative physiology so they can anticipate specific postoperative problems, recognize trends in clinical status, and develop an appropriate plan of care. This paper reviews the first 2 stages of single-ventricle palliation, relevant modifications to the Fontan procedure, important preoperative cardiac catheterization data, common postoperative problems, and outcomes after the Fontan procedure. (*Critical Care Nurse*. 2018;38[1]:e1-e10)

The Fontan procedure is the final stage in the single-ventricle palliation pathway and is usually performed on patients between the ages of 18 months and 4 years.¹ The goal of the Fontan procedure is to completely separate pulmonary and systemic blood flow, thereby preventing the mixing of oxygenated and deoxygenated blood.² Systemic venous return is passively diverted through the Fontan circuit directly to the pulmonary arteries and the lungs without any ventricular contribution to flow. Since its inception, the surgical procedure has undergone many modifications to optimize the hemodynamics and minimize the risks. As with the surgical modifications, postoperative management has evolved as our understanding of the complex cardiopulmonary interactions has improved.

CE 1.0 hour, CERP A

This article has been designated for CE contact hour(s). The evaluation tests your knowledge of the following objectives:

1. Articulate the purpose of the Fontan operation.
2. Describe the major modifications to the Fontan operation.
3. Explain common postoperative problems after the Fontan operation.

To complete evaluation for CE contact hour(s) for activity C1813, visit www.ccnonline.org and click the "CE Articles" button. No CE fee for AACN members. This activity expires on February 1, 2021.

The American Association of Critical-Care Nurses is an accredited provider of continuing nursing education by the American Nurses Credentialing Center's Commission on Accreditation. AACN has been approved as a provider of continuing education in nursing by the State Boards of Registered Nursing of California (#01036) and Louisiana (#LSBN12).

©2018 American Association of Critical-Care Nurses doi: <https://doi.org/10.4037/ccn2018994>

Critical care nurses caring for patients undergoing Fontan procedures must have a solid understanding of the preoperative data, risk factors, and unique postoperative physiology so they can anticipate specific postoperative problems, recognize trends in clinical status, and develop an appropriate plan of care. This paper briefly reviews the first 2 stages of single-ventricle palliation and 4 major modifications to the Fontan procedure, covers the important preoperative cardiac catheterization data, describes common postoperative problems, and briefly discusses outcomes after the Fontan procedure.

Brief Review of Stages I and II

Patients with a single ventricle have complex anatomy that requires staged palliation. Patients with systemic outflow tract obstruction and/or hypoplasia (eg, hypoplastic left heart syndrome) undergo a Norwood-type operation in the newborn period. The Norwood operation can be described in 4 parts: (1) reconstructing the aortic arch with the native proximal main pulmonary artery, usually supplemented with homograft tissue; (2) establishing pulmonary blood flow with a right ventricle to pulmonary artery Sano shunt or a systemic to pulmonary artery modified Blalock-Taussig shunt; (3) performing an atrial septectomy; and (4) ligating the patent ductus arteriosus.

Patients with single-ventricle anatomy and obstruction to pulmonary blood flow receive palliation in the newborn period with a systemic to pulmonary artery shunt such as the modified Blalock-Taussig shunt. Patients who have single-ventricle anatomy without systemic or pulmonary outflow obstruction may have pulmonary overcirculation and require pulmonary artery banding to protect the pulmonary vasculature from excessive blood flow and optimize systemic output. Patients who maintain a balanced circulation with adequate pulmonary and systemic blood flow in early infancy

are spared neonatal surgery. Their initial palliation is the stage II procedure.

Stage II may be a bidirectional Glenn or a hemi-Fontan procedure. Although these are different procedures, the postoperative physiology is almost identical. The bidirectional Glenn shunt is an end-to-side anastomosis of the superior vena cava to the pulmonary artery. The hemi-Fontan procedure maintains the native superior vena cava to right atrial junction and is an anastomosis of this confluence to the branch pulmonary artery using a homograft dam to redirect superior vena cava flow to the pulmonary arteries. The major goal of the stage II procedure is to reduce the volume load on the single ventricle by directing the systemic venous return from the upper body directly to the lungs via the superior cavopulmonary connection. The reduced volume load that is achieved with the bidirectional Glenn procedure improves diastolic function and reduces the ventricular wall thickness at the time of the Fontan procedure.³

Historical Context and Fontan Procedure Modifications

In 1971, Fontan² described 3 patients with tricuspid atresia who underwent a procedure that separated pulmonary and systemic blood flow. Fontan indicated that this procedure, first performed in 1968, was an option for a well-developed child without evidence of pulmonary arterial hypertension. The surgical procedure he described was an anastomosis of the superior vena cava to the right pulmonary artery and a separate anastomosis between the right atrium and the proximal end of the left pulmonary artery (Figure 1). The procedure was designed to use the pulsatility from the right atrium to direct blood from the inferior vena cava (IVC) to the left pulmonary artery. To achieve this, homograft valves were placed between the IVC and right atrium and between the right atrium and left pulmonary artery, and the atrial septal defect was closed. Arrhythmias, valve calcification, elevated right heart pressures, and limited application to other single-ventricle lesions led to the second-generation Fontan procedure: the lateral tunnel.⁴

The lateral tunnel procedure, first performed in 1987, is a baffle or tunnel placed within the right atrium to direct IVC blood to the pulmonary arteries (Figure 2). Systemic venous return from both the IVC and superior vena cava is separated from pulmonary venous return and flows directly to the lungs without any ventricular contribution.

Author

Melissa Beaudet Jones is a nurse practitioner and ventricular assist device coordinator in the cardiac intensive care unit at Children's National Health System in Washington, DC.

Corresponding author: Melissa Beaudet Jones, MSN, APRN, CPNP-AC, Cardiac Intensive Care Unit, Children's National Health System, 111 Michigan Ave, NW, Washington, DC (email: mejones@childrensnational.org).

To purchase electronic or print reprints, contact the American Association of Critical-Care Nurses, 101 Columbia, Aliso Viejo, CA 92656. Phone, (800) 899-1712 or (949) 362-2050 (ext 532); fax, (949) 362-2049; email, reprints@aacn.org.

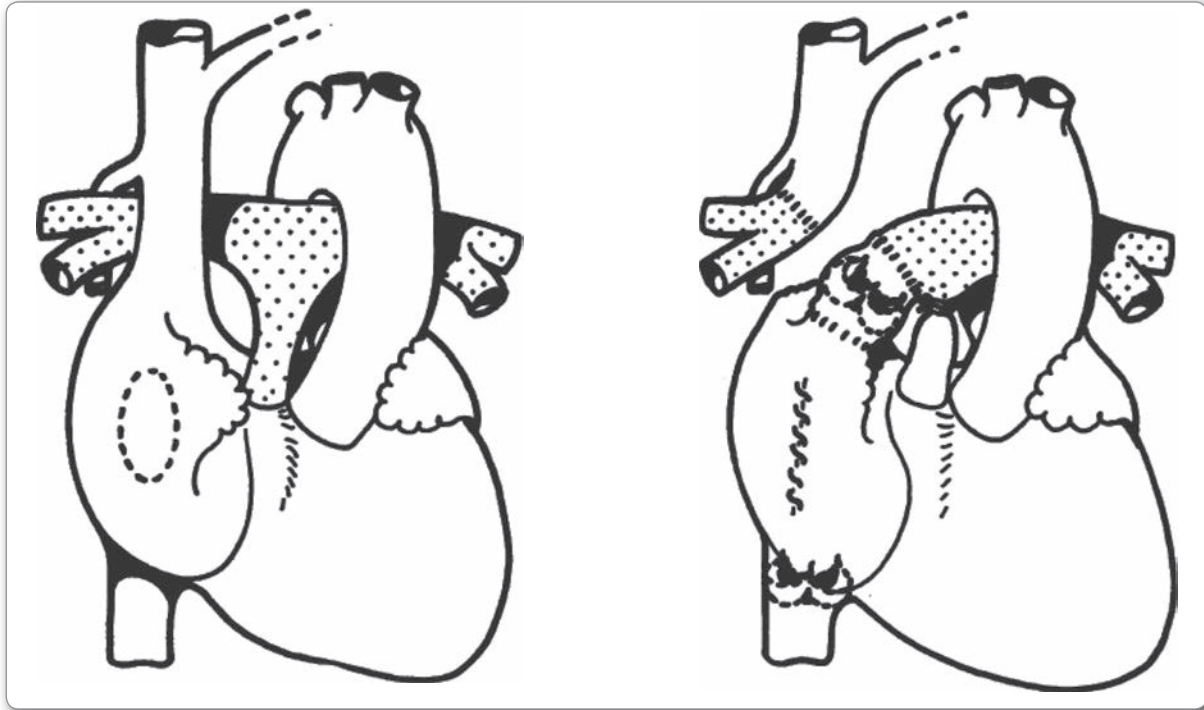


Figure 1 Steps in surgical repair: (1) end-to-side anastomosis of distal end of right pulmonary artery to superior vena cava; (2) end-to-end anastomosis of right atrial appendage to proximal end of right pulmonary artery by means of an aortic valve homograft; (3) closure of atrial septal defect; (4) insertion of a pulmonary valve homograft into inferior vena cava; and (5) ligation of main pulmonary artery.

Reprinted with permission from *Thorax BMJ*, 1971.

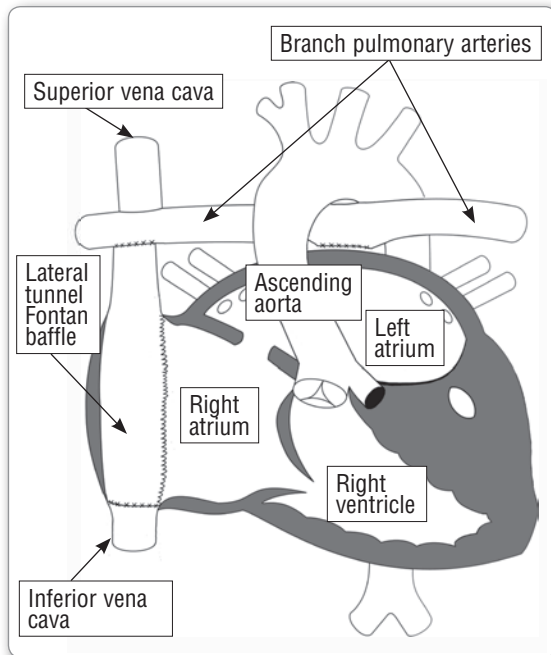


Figure 2 Lateral tunnel Fontan procedure.

Reprinted with permission from Jones et al.⁵ Illustration by Dr Joshua Kanter.

It became apparent that atrial pulsatility did not aid in pulmonary blood flow. In fact, the exposure of elevated right-sided pressures on the atrium may be detrimental to pulmonary venous return.^{4,6} Because of a new understanding of this physiology and the fact that late atrial arrhythmias were common complications after the Fontan procedure, Marcelletti et al⁷ described the extracardiac conduit Fontan procedure in 1990 (Figure 3). The extracardiac Fontan procedure is a tunnel or baffle that connects the IVC to the pulmonary arteries without entering the right atrium, so the pathway is completely outside the heart. This modification is useful in patients with complex atrial anatomy, venous connections, or coronary sinusoids because in some cases it does not require cardiopulmonary bypass.

The Fontan fenestration, first described in the early 1990s, is a hole that creates a connection between the Fontan pathway or baffle and the left side of the heart. This technique is used to decompress the high Fontan pathway pressures and augment cardiac output in the early postoperative period. Bridges and colleagues⁸ found that a Fontan baffle fenestration in high-risk

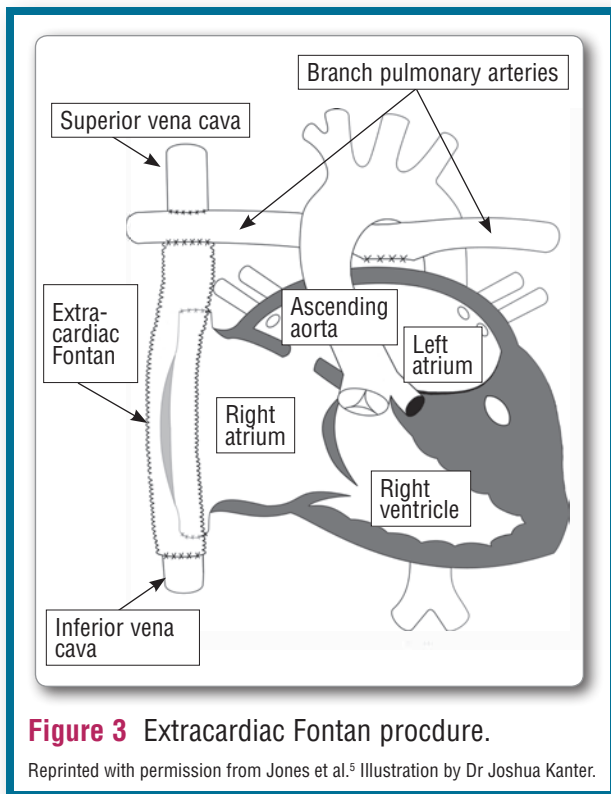


Figure 3 Extraductal Fontan procedure.

Reprinted with permission from Jones et al.⁵ Illustration by Dr Joshua Kanter.

patients was associated with low mortality, significantly lower incidence of pleural effusion, and significantly shorter hospitalization. The lateral tunnel Fontan procedure is easily fenestrated, but atrial arrhythmias are common postoperative complications, perhaps because of surgical manipulation within the atrium.⁴ Given the location of the extracardiac conduit, maintaining fenestration patency with this modification became a significant challenge.

An intracardiac or extracardiac conduit with fenestration is the most recent major modification to the original Fontan procedure (Figure 4). The intention of the intracardiac or extracardiac conduit is to combine the benefits of the lateral tunnel and the extracardiac conduit and minimize their disadvantages. A ring-supported conduit is sutured to the IVC, a fenestration is easily placed in this portion of the conduit, and then the conduit emerges from the side of the right atrium (avoiding the sinus node) and is anastomosed to the bidirectional Glenn shunt.⁴ Sinha and colleagues⁹ found that the intracardiac or extracardiac conduit has a significantly lower risk of short- and intermediate-term postoperative arrhythmias than does the lateral tunnel modification. More data are needed to evaluate the association between the intracardiac or extracardiac conduit and long-term arrhythmias.

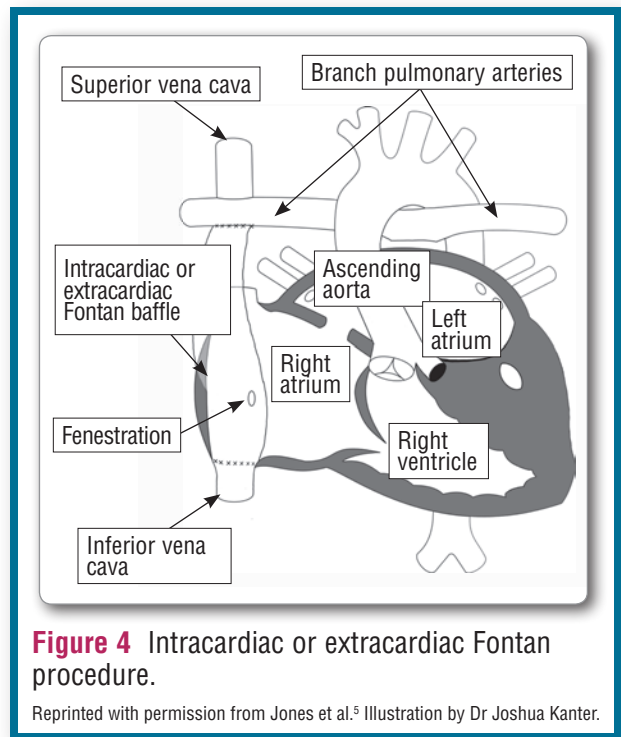


Figure 4 Intracardiac or extracardiac Fontan procedure.

Reprinted with permission from Jones et al.⁵ Illustration by Dr Joshua Kanter.

Critical care nurses' understanding of the specific type of Fontan procedure and the patient-specific anatomy and physiology is essential to prepare for the postoperative course. The next section reviews specific preoperative anatomic and physiologic findings pertinent to postoperative Fontan procedure management.

Review of Preoperative Cardiac Catheterization Data

Careful review of preoperative data is essential to understand the postoperative physiology and anticipate postoperative problems. Before the Fontan procedure, patients undergo a cardiac catheterization to evaluate the anatomy and obtain hemodynamic measurements needed for surgical planning and postoperative management.

Important hemodynamic and anatomic information from a pre-Fontan cardiac catheterization includes but is not limited to the following: assessment of the atrial septum, systemic outflow tract, aortic arch, pulmonary arteries, and atrioventricular valve; measurement of end-diastolic pressure, systolic function of the single ventricle, pulmonary venous saturation, mean pulmonary artery pressure, and pulmonary vascular resistance (PVR); and identification of any aortopulmonary or venovenous collaterals. The transpulmonary gradient, the pressure gradient across the pulmonary vasculature, is measured. Maintaining a low transpulmonary gradient

is key to optimizing left atrial return and cardiac output in the postoperative period.¹⁰

An unrestrictive atrial septal communication is necessary in most, although not all, patients with single-ventricle anatomy. With a single right ventricle, an unrestrictive atrial septum is essential for shunting pulmonary venous return to the right side of the heart. With a single left ventricle, an unrestrictive septum is needed to ensure unobstructed systemic venous return to the left side. If there is a double-inlet single ventricle with 2 adequate atrioventricular valves, an unrestrictive atrial septal defect is not essential.

The aorta may have been reconstructed during a Norwood procedure and may have residual narrowing or recoarctation. Residual stenosis of the systemic outflow causing increased afterload will increase end-diastolic pressure, a marker of ventricular compliance of the single ventricle. An end-diastolic pressure of less than 10 mm Hg is generally considered low to medium risk.¹⁰ An area of stenosis in the systemic outflow may require dilation during the pre-Fontan cardiac catheterization to optimize the ventricular function and cardiac output postoperatively.

Pulmonary artery continuity and caliber are important to ensure adequate pulmonary blood flow. Areas of stenosis identified at the pre-Fontan evaluation can be addressed at the time of catheterization or during surgery. Expected pulmonary venous saturation is greater than 96%. Pulmonary venous desaturation may indicate parenchymal lung disease, arteriovenous malformations, or venovenous collaterals. Preoperative pulmonary venous desaturation may help explain desaturation in the postoperative period. Low mean pulmonary artery pressure and PVR are ideal for optimal Fontan hemodynamics.¹⁰

Synthesizing anatomic and physiologic data with the surgical approach can help identify risk factors preoperatively and inform postoperative management. Analysis of the Single Ventricle Reconstruction Trial cohort of patients revealed that the patient's length of stay after stage II procedures before the Fontan procedure and at least moderate tricuspid regurgitation were associated with a longer length of stay after the Fontan operation.¹¹ Sasaki et al¹² recently conducted a retrospective review of 214 patients who had undergone a Fontan procedure and found that evidence of compromised preoperative pulmonary blood flow, low oxygen saturation, high hemoglobin level, and elevated pulmonary artery pressure were associated with longer hospital

stays. Gentles and colleagues¹³ found that a mean pulmonary artery pressure of 19 mm Hg or greater, pulmonary artery distortion, the absence of a fenestration, and heterotaxy syndrome were risk factors for early Fontan procedure failure. Overall medical complexity, tricuspid valve incompetence, and elevated pulmonary artery pressure place patients at risk for a prolonged hospital stay at the time of the Fontan operation.

Postoperative Nursing Considerations: Low Cardiac Output

Low cardiac output syndrome is the temporary state of inadequate tissue perfusion that is the result of myocardial dysfunction. Critical care nurses continuously evaluate the adequacy of cardiac output through frequent focused physical assessments, evaluation of vital signs, and interpretation of the laboratory data.¹⁴ Physical assessment findings consistent with inadequate cardiac output are delayed capillary refill time, cool extremities, weak pulses, poor urine output, and fluid overload. Vital signs suggestive of low cardiac output include the following: tachycardia, hypotension, low oxygen saturation. Laboratory data suggestive of low cardiac output include metabolic acidosis, elevated lactate level, low mixed venous oxygen saturation, elevated serum creatinine level, and elevated liver enzyme levels. Intracardiac pressure monitoring is an extremely useful tool to measure the transpulmonary gradient (TPG), determine the

potential causes of low cardiac output, and target specific interventions to improve the

Critical care nurses caring for patients undergoing Fontan procedures must be able to anticipate postoperative problems, recognize trends in clinical status, and develop an appropriate plan of care.

underlying cause. Quickly and accurately diagnosing and treating low cardiac output in patients who have undergone Fontan procedures are critical to their short- and long-term outcomes. These patients are at high risk for neurologic injury and impairment from chronic cyanosis, polycythemia, hypotension, and high central venous pressure, which may impair cerebral blood flow.

A major goal of postoperative management of a patient after a Fontan procedure is to maintain a low TPG to allow for adequate pulmonary blood flow and cardiac output. In a postoperative patient, the TPG can be measured by subtracting the left atrial pressure from the

Table 1 Low cardiac output syndrome in patients after a fenestrated Fontan procedure^{10,15}

| Fontan pressure (CVP) | Left atrial pressure | Transpulmonary gradient (reference <7 mm Hg) | Oxygen saturation with fenestration (reference 75%-100%) | Differential diagnosis | Diagnostics and treatment |
|-----------------------|----------------------|--|--|--|--|
| ↑ | ↓ | >7 mm Hg | ↓ | Decreased pulmonary blood flow → increased shunt across fenestration Elevated PVR Fontan pathway obstruction or thrombosis Pulmonary artery branch stenosis | Increase FiO ₂ Consider nitric oxide Consider early extubation Consider cardiac catheterization to diagnose anatomic obstruction to pulmonary blood flow If thrombus suspected, consider thrombolytic treatment |
| ↑ | ↓ | >7 mm Hg | ↑ | Fenestration closed/thrombosed | Consider cardiac catheterization to open fenestration Consider thrombolytic treatment |
| ↓ | ↓ | <7 mm Hg | ↑ ↓ | Hypovolemia | Replete volume |
| ↑ | ↑ | <7 mm Hg | ↑ ↓ | Arrhythmia Diastolic dysfunction Residual systemic outflow tract obstruction Atrioventricular valve insufficiency Tamponade | Manage arrhythmia Reduce afterload Consider cardiac catheterization to diagnose and treat systemic outflow tract obstruction Evaluate for tamponade with echocardiogram Milk chest tubes and reposition patient to encourage chest tube drainage |

Abbreviations: CVP, central venous pressure; FiO₂, fraction of inspired oxygen; PVR, pulmonary vascular resistance.

Fontan pressure. The goal TPG in the immediate postoperative period should be less than 7 mm Hg.¹⁰ Determining the transpulmonary gradient helps diagnose the cause of low cardiac output and develop targeted interventions to address the specific problem (Table 1).

Low Cardiac Output and High TPG

In a patient with low cardiac output and an elevated TPG, physical assessment may reveal an enlarged liver, tachycardia, hypotension, and poor peripheral perfusion. Care is aimed at reducing PVR and evaluating for anatomic obstruction to pulmonary blood flow.¹⁰ Interventions to reduce PVR are important because physiologic obstruction to pulmonary blood flow impedes left atrial return and cardiac output. Strategies to reduce PVR include avoiding and correcting acidosis, using pulmonary vasodilator therapy (oxygen and/or inhaled nitric oxide), and removing positive-pressure ventilation as soon as appropriate. Positive-pressure ventilation impedes systemic venous return and can increase PVR,

reducing pulmonary blood flow.¹⁶ When patient ventilation is maintained at or near functional residual capacity, PVR is lowest. If a patient is able to breathe spontaneously and maintain functional residual capacity without mechanical support, then removal of positive-pressure ventilation will improve PVR and hemodynamics. On the other hand, if positive-pressure ventilation is required to maintain functional residual capacity and removal of positive pressure causes atelectasis, then PVR will rise and cause hemodynamics to deteriorate.¹⁷

Suspicion of a thrombosis in the Fontan pathway may require anticoagulation until the diagnosis can be confirmed by echocardiography and, when necessary, cardiac catheterization. If the Fontan is fenestrated, fenestration thrombosis should be considered when a patient has a high TPG and high oxygen saturation. Some patients may maintain adequate cardiac output without a patent fenestration, although others may have signs of low cardiac output and may need an urgent cardiac catheterization to open the fenestration. In the face

of poor hemodynamics, anticoagulation therapy may be needed to prevent further thrombus formation before the diagnosis is confirmed in the cardiac catheterization laboratory. Persistent pleural effusions, hepatic congestion and dysfunction, protein-losing enteropathy, plastic bronchitis, and atrial arrhythmias are symptoms of long-standing elevated Fontan pressure.¹⁸

Low Cardiac Output and Low Atrial Pressures

A TPG of less than 7 mm Hg, with low Fontan and left atrial pressures, tachycardia, and hypotension, can indicate intravascular volume depletion and the need for volume resuscitation.¹⁰ Capillary leakage, postoperative hemorrhage, high-volume chest tube drainage, and excessive diuretic administration may contribute to a hypovolemic state. Urgent volume resuscitation is needed to restore adequate cardiac output given that pulmonary blood flow is completely passive and therefore cannot be augmented with increased contractility or heart rate.

Low Cardiac Output and High Atrial Pressures

Elevated intracardiac pressures with a normal TPG, hypotension, poor peripheral perfusion, and tachycardia may suggest ventricular dysfunction, tamponade, arrhythmia causing atrioventricular dyssynchrony, and atrioventricular valve incompetence.¹⁵ An echocardiogram will help diagnose atrioventricular valve regurgitation, tamponade, and poor systolic function, although diastolic dysfunction is difficult to quantify using echocardiography. Afterload reduction and inotropy may be needed to support ventricular dysfunction.¹⁰ Although positive-pressure ventilation reduces systemic venous return and pulmonary blood flow, it reduces afterload for the systemic ventricle, which may actually improve hemodynamics in the setting of severe ventricular dysfunction. Decisions about how to best support a patient with a Fontan procedure and poor ventricular function require careful consideration of the risks and benefits of positive-pressure ventilation.

If tamponade is suspected, while the cardiac surgeons consider a bedside sternotomy the bedside nurse must ensure chest tube patency by milking the chest tubes and repositioning the patient to promote drainage. The bedside nurse may also need to prepare volume resuscitation and emergency medications in the event of an acute decompensation from tamponade physiology requiring an emergency bedside sternotomy.

Junctional ectopic tachycardia, a common arrhythmia after the Fontan operation, causes atrioventricular dyssynchrony because atrial contraction occurs against a closed atrioventricular valve. Loss of atrioventricular synchrony leads to elevated left atrial pressure, and cardiac output suffers without the atrial “kick.” Reducing catecholamine administration (if tolerated), avoiding hyperthermia, perhaps cooling the patient to 35°C to 36°C, and administering sedation help slow the junctional rate and allow for external atrial pacing. Vasopressin may be considered if blood pressure support is needed while weaning the patient off catecholamines. Administration of antiarrhythmics, commonly amiodarone or procainamide, may also prevent recurrence of the arrhythmia.¹⁹

Atrioventricular valve incompetence causes regurgitant blood flow to the atrium during systole, which will cause elevated atrial and pulmonary venous pressure and subsequently compromise cardiac output. Medical management of atrioventricular valve insufficiency is aimed at afterload reduction to reduce the regurgitant volume¹⁰ and diuretic therapy to treat pulmonary edema.

Postoperative Nursing Considerations: Hypoxemia

Normal postoperative oxygen saturation in a patient after a fenestrated Fontan procedure ranges from 75% to 100%. After a nonfenestrated Fontan procedure, oxygen saturation should be in the reference range of 96% to 100%. Hypoxemia in a patient after a Fontan procedure has 3 major causes: pulmonary venous desaturation, low mixed venous oxygen saturation after a fenestrated Fontan procedure, or a high TPG causing increased right to left shunting across the fenestration.

The Fontan fenestration is used to decompress the high Fontan pathway pressures and augment cardiac output in the early postoperative period.

Acute desaturation in a patient who has undergone a Fontan procedure can be treated with administration of nitric oxide or 100% inspired oxygen.

Pulmonary venous desaturation can result from a variety of pathologies that can generally be diagnosed by chest radiography. These pathologies include pneumothorax, pulmonary edema, atelectasis, pleural effusion, pneumonia, and parenchymal lung disease.¹⁰ Treatment of a pneumothorax requires evacuation of air by needle

decompression or by placement of a pleural tube. Pulmonary edema is treated with diuretic therapy. Atelectasis may be the result of mucus plugs requiring endotracheal tube suctioning. A malpositioned endotracheal tube may also cause atelectasis and must be evaluated, repositioned, and secured. Once positive-pressure ventilation has been discontinued, encouraging the patient to cough and breathe deeply by using bubbles or an incentive spirometer may help prevent atelectasis. Pleural effusion, the accumulation of fluid in the pleural space, may be treated conservatively with diuretics. However, if the effusion is large and impacts ventilation, a chest tube may be placed to drain the fluid and allow full expansion of the lung. Pneumonia may require antibiotic treatment and supportive therapy until it resolves. Parenchymal lung disease may be treated with chronic medications in addition to the routine postoperative diuretics. A preoperative finding of pulmonary venous desaturation may suggest that the

Both lateral tunnel and extracardiac Fontan procedures have better outcomes than those with atriopulmonary connections.

patient has an element of underlying lung disease, and normal oxy-

gen saturation should not be the goal. Pulmonary arteriovenous malformations, another cause of pulmonary venous desaturation, cause pulmonary artery blood to bypass the capillaries and not become oxygenated before returning to the left atrium. Similarly, venovenous collateral vessels form a direct connection between the systemic venous drainage and the pulmonary venous drainage, thereby directing deoxygenated blood to the left atrium.²⁰ Cardiac catheterization intervention may be necessary to occlude the collateral vessels.

A low mixed venous saturation can be the result of anemia or of a highly consumptive state such as low cardiac output, fever, agitation, or sepsis. Low mixed venous saturations after a fenestrated Fontan procedure may cause shunting of desaturated blood to the systemic circulation. Treatment measures aimed at normalizing hemoglobin, augmenting cardiac output, and reducing oxygen demand by avoiding fever and agitation will optimize mixed venous oxygen saturation and overall oxygen delivery.

Finally, a patient who has undergone a fenestrated Fontan procedure will be hypoxic as a result of increased right to left shunting across the fenestration if there is an anatomic or physiologic obstruction to pulmonary

blood flow. Cardiac catheterization may be necessary to diagnose and treat a pulmonary artery stenosis. Thrombolytics may be needed to treat a thrombus in the Fontan pathway or pulmonary arteries. Measures to reduce PVR, including early extubation when appropriate, avoiding acidosis, increasing the fraction of inspired oxygen, and using nitric oxide, must also be considered (Table 2).

Outcomes

Given the evolution of the Fontan procedure, timing and specific technique must be considered when evaluating outcomes. Multicenter data have shown 1% to 2% hospital mortality after Fontan procedures.¹ In 2013, Stewart et al²¹ reviewed the Society of Thoracic Surgeons Congenital Heart Surgery Database to evaluate outcomes according to the type of Fontan procedure (lateral tunnel or extracardiac). The extracardiac Fontan procedure was associated with significantly higher rates of Fontan failure and Fontan takedown as well as a longer hospital length of stay. However, both lateral tunnel and extracardiac Fontan procedures have better outcomes than those with atriopulmonary connections.²² The survival rate for patients who have the Fontan operation today is 85% at 30 years.¹ Interestingly, only between 4% and 7% of patients receive a heart transplant within 20 years of the Fontan procedure.¹ Perhaps the multisystem burden of disease precludes transplant candidacy in patients with a Fontan procedure who present in the late stages of heart failure. In a systematic review and meta-analysis, Doumouras and colleagues²³ compared transplant survival between patients with and without congenital heart disease. Patients with congenital heart disease had higher early mortality after transplantation but lower late mortality rates.

Long-term problems for patients who have undergone a Fontan procedure are exercise intolerance, arrhythmias, atrioventricular valve disease, ventricular dysfunction, liver and renal dysfunction, thromboembolic events, protein-losing enteropathy, and neurodevelopmental delays.¹ Infants with congenital heart disease have abnormal and immature fetal brain development.²⁴ They often undergo palliative surgery requiring cardiopulmonary bypass in the neonatal period and then as infants and toddlers, during periods of critical brain development. These factors, along with repeated anesthetic exposure, abnormal cerebral perfusion pressures resulting from elevated central venous pressure, and

Table 2 Hypoxemia in patients after a Fontan procedure^{10,15}

| Physiology | Etiology | Diagnostics and treatment |
|---|---|---|
| Pulmonary venous desaturation | Pleural effusion Pneumothorax Atelectasis Pulmonary edema Pneumonia Pulmonary arteriovenous malformations Venovenous collateral vessels | Chest radiograph to diagnose parenchymal lung disease Cardiac catheterization to diagnose pulmonary vascular problems Drainage of pleural effusion Evacuation of pneumothorax Endotracheal suctioning Antibiotics to treat pneumonia Occlusion of collateral vessels (catheterization laboratory) |
| Low mixed venous oxygen saturation | Anemia Low cardiac output state Highly consumptive state (eg, fever, agitation, or sepsis) | Optimize hemoglobin Optimize cardiac output Avoid fever Avoid excessive agitation |
| High transpulmonary gradient (low pulmonary blood flow and increased right to left shunt across fenestration) | Anatomic obstruction to pulmonary blood flow (pulmonary stenosis, thrombus) Elevated pulmonary vascular resistance Positive-pressure ventilation | Perform cardiac catheterization to diagnose and treat obstruction to pulmonary blood flow Consider thrombolytic treatment for pulmonary artery thrombus Optimize pulmonary vascular resistance: extubate early if possible, avoid acidosis, use oxygen and nitric oxide |

long-term hospitalizations, increase the risk of short- and long-term neurodevelopmental, behavioral, and learning impairments.^{25,26} Although mortality rates have improved over the past several decades, these patients face significant complex morbidity. Given the low mortality rates, the focus has shifted to better understand the multi-system effects of single-ventricle physiology and improve the quality of life for those living with the disease.

Conclusion

The Fontan procedure has undergone several modifications, and the complex postoperative physiology of patients who have had Fontan operations has become more evident since the procedure's inception in 1968. The cardiopulmonary interactions are unique to this specific stage of palliation. The physiology is dynamic and sensitive to changes in fluid status, ventilation modes, anemia, and cardiac function. Equipped with a strong understanding of this physiology, nurses are well positioned to optimize postoperative outcomes. Critical care nurses' ability to synthesize preoperative data, operative course, and postoperative clinical findings will inform proactive management of postoperative problems. Early recognition of low cardiac output or hypoxemia in the postoperative period and an understanding

of the possible causes will expedite interventions to optimize oxygen delivery. [CCN](#)

Acknowledgments

The author thanks Dot Beke, Sandy Staveski, and Drs Richard A. Jonas, John T. Berger, Darren Klugman, and Joshua Kanter for their guidance.

Financial Disclosures

None reported.

eLetters

Now that you've read the article, create or contribute to an online discussion about this topic using eLetters. Just visit www.ccnonline.org and select the article you want to comment on. In the full-text or PDF view of the article, click "Responses" in the middle column and then "Submit a response."

See also

To learn more about pediatric cardiovascular care, read "Measurement of Quality of Nursing Practice in Congenital Cardiac Care" by Connor et al in the *American Journal of Critical Care*, March 2016;25:128-135. Available at www.ajconline.org.

References

- Ohye RG, Schranz D, D'Udekem Y. Current therapy for hypoplastic left heart syndrome and related single ventricle lesions. *Circulation*. 2016; 134(17):1265-1279.
- Fontan F, Baudet E. Surgical repair of tricuspid atresia. *Thorax*. 1971; 26(3):240-248.
- Pridjian AK, Mendelsohn AM, Lupinetti FM, et al. Usefulness of the bidirectional Glenn procedure as staged reconstruction for the functional single ventricle. *Am J Cardiol*. 1993;71(11):959-962.
- Jonas RA. The intra/extracardiac conduit fenestrated Fontan. *Semin Thorac Cardiovasc Surg Pediatr Card Surg Annu*. 2011;14(1):11-18.
- Jones MB, Klugman D, Fitzgerald R, et al. *Pediatric Cardiac Intensive Care Handbook*. Washington, DC: Pediatric Cardiac Intensive Care Society; 2015.

6. DiSessa TG, Child JS, Perloff JK, et al. Systemic venous and pulmonary arterial flow patterns after Fontan's procedure for tricuspid atresia or single ventricle. *Circulation*. 1984;70(5):898-902.
7. Marcelletti C, Corno A, Giannico S, Marino B. Inferior vena cava-pulmonary artery extracardiac conduit. A new form of right heart bypass. *J Thorac Cardiovasc Surg*. 1990;100(2):228-232.
8. Bridges ND, Mayer JE Jr, Lock JE, et al. Effect of baffle fenestration on outcome of the modified Fontan operation. *Circulation*. 1992;86(6):1762-1769.
9. Sinha P, Zurakowski D, He D, et al. Intra/extracardiac fenestrated modification leads to lower incidence of arrhythmias after the Fontan operation. *J Thorac Cardiovasc Surg*. 2013;145(3):678-682.
10. Nichols DG, Ungerleider RM, Spevak PJ, et al. *Critical Heart Disease in Infants and Children*. 2nd ed. Philadelphia, PA: Mosby; 2006.
11. Ravishankar C, Gerstenberger E, Sleeper LA, et al; Pediatric Heart Network Investigators. Factors affecting Fontan length of stay: results from the Single Ventricle Reconstruction trial. *J Thorac Cardiovasc Surg*. 2016;151(3):669-675.e1.
12. Sasaki J, Dykes JC, Sosa LJ, et al. Risk factors for longer hospital stay following the Fontan operation. *Pediatr Crit Care Med*. 2016;17(5):411-419.
13. Gentles TL, Mayer JE Jr, Gauvreau K, et al. Fontan operation in five hundred consecutive patients: factors influencing early and late outcome. *J Thorac Cardiovasc Surg*. 1997;114(3):376-391.
14. Massé L, Antonacci M. Low cardiac output syndrome: identification and management. *Crit Care Nurse Clin North Am*. 2005;17(4):375-383.
15. Sanders SP, Wright GB, Keane JF, Norwood WI, Castaneda AR. Clinical and hemodynamic results of the Fontan operation for tricuspid atresia. *Am J Cardiol*. 1982;49(7):1733-1740.
16. Bronicki RA, Penny DJ, Anas NG, Fuhrman B. Cardiopulmonary interactions. *Pediatr Crit Care Med*. 2016;17(8 suppl 1):S182-S193.
17. Shekerdemian L, Bohn D. Cardiovascular effects of mechanical ventilation. *Arch Dis Child*. 1999;80(5):475-480.
18. Mavroudis C, Deal BJ. Fontan conversion: literature review and lessons learned over 20 years. *World J Pediatr Congenit Heart Surg*. 2016;7(2):192-198.
19. Payne L, Zeigler VL, Gillette PC. Acute cardiac arrhythmias following surgery for congenital heart disease: mechanisms, diagnostic tools, and management. *Crit Care Nurse Clin North Am*. 2011;23(2):255-272.
20. Poterucha JT, Johnson JN, Taggart NW, et al. Embolization of venovenous collaterals after the Fontan operation is associated with decreased survival. *Congenit Heart Dis*. 2015;10(5):E230-236.
21. Stewart RD, Pasquali SK, Jacobs JP, et al. Contemporary Fontan operation: association between early outcome and type of cavopulmonary connection. *Ann Thorac Surg*. 2012;93(4):1254-1260, discussion 1261.
22. d'Udekem Y, Iyengar AJ, Galati JC, et al. Redefining expectations of long-term survival after the Fontan procedure: twenty-five years of follow-up from the entire population of Australia and New Zealand. *Circulation*. 2014;130(11 suppl 1):S32-S38.
23. Doumouras BS, Alba AC, Foroutan F, Burchill LJ, Dipchand AI, Ross HJ. Outcomes in adult congenital heart disease patients undergoing heart transplantation: a systematic review and meta-analysis. *J Heart Lung Transplant*. 2016;35(11):1337-1347.
24. Donofrio MT, Duplessis AJ, Limperopoulos C. Impact of congenital heart disease on fetal brain development and injury. *Curr Opin Pediatr*. 2011;23(5):502-511.
25. Saiki H, Kurishima C, Masutani S, Senzaki H. Cerebral circulation in patients with Fontan circulation: assessment by carotid arterial wave intensity and stiffness. *Ann Thorac Surg*. 2014;97(4):1394-1399.
26. International Cardiac Collaborative on Neurodevelopment (ICCON) Investigators. Impact of operative and postoperative factors on neurodevelopmental outcomes after cardiac operations. *Ann Thorac Surg*. 2016;102(3):843-849.